

ORIGINAL ARTICLE

## Combination blue (415 nm) and red (633 nm) LED phototherapy in the treatment of mild to severe acne vulgaris

DAVID J. GOLDBERG<sup>1,2</sup> & BRUCE A. RUSSELL<sup>3</sup>

<sup>1</sup>Skin Laser & Surgery Specialists of New York/New Jersey, New York, NY, USA, <sup>2</sup>Department of Dermatology, Mount Sinai School of Medicine, New York, NY, USA, and <sup>3</sup>Advanced Laser and Dermatologic Surgery Clinics PC, Beaverton, OR, USA

### Abstract

**Background and objective:** Acne vulgaris represents both a challenge to the treating dermatologist and a major concern for the patient. Conventional treatments have proved inconsistent with often unacceptable side effects and high rates of recurrence. Non-thermal, non-laser, phototherapy for acne with a combination of blue and red light has recently attracted attention. The present study was designed to assess the efficacy of this combination phototherapy.

**Methods:** Twenty-four subjects, Fitzpatrick skin types II–V, with mild to severe symmetric facial acne vulgaris were recruited for the study. Subjects were well matched at baseline in terms of both age and duration of acne. Subjects were treated over eight sessions, two per week 3 days apart, alternating between 415 nm blue light (20 minutes/session, 48 J/cm<sup>2</sup>) and 633 nm red light (20 minutes/session, 96 J/cm<sup>2</sup>) from a light-emitting diode (LED)-based therapy system. Patients received a mild microdermabrasion before each session. Acne was assessed at baseline and at weeks 2, 4, 8 and 12.

**Results:** Twenty-two patients completed the trial. A mean reduction in lesion count was observed at all follow-up points. At the 4-week follow-up, the mean lesion count reduction was significant at 46% ( $p=0.001$ ). At the 12-week follow-up, the mean lesion count reduction was also significant at 81% ( $p=0.001$ ). Patient and dermatologist assessments were similar. Severe acne showed a marginally better response than mild acne. Side effects were minimal and transitory. Comedones did not respond as well as inflammatory lesions.

**Conclusions:** Combination blue and red LED therapy appears to have excellent potential in the treatment of mild to severe acne. Treatment appears to be both pain- and side effect-free.

**Key words:** LED, light-emitting diodes, photorejuvenation

### Introduction

Acne vulgaris is a common disorder estimated to affect 80% of the population and account for over 30% of annual dermatology visits. The disease carries significant potential for physical and psychological scarring (1).

The mainstays of current acne treatment are antibiotics and retinoids, though patient success rates vary in these treatments. Development of bacterial resistance in antibiotic therapy is widely documented (2), whereas retinoid therapy carries a poor side-effect profile and displays teratogenicity (3). Topical preparations may also cause significant side effects, including skin irritation, and their effects may mimic skin deterioration leading to non-compliance with treatment (4). There is a growing

demand by patients for an effective, safe and side effect-free treatment for acne (5,6). Photodynamic therapy is suggested as one such modality.

Photodynamic therapy is the use of light to activate exogenously administered or endogenously formed photosensitizers. This results in the formation of singlet oxygen and reactive radicles leading to bacterial destruction. *Propionibacterium acnes* is a gram positive bacteria implicated in the pathophysiology of acne. *P. acnes* synthesizes the photosensitizing compounds protoporphyrin and coproporphyrin as part of normal metabolism (5–7).

These endogenous porphyrins achieve optimum photoexcitation when irradiated with 407–420 nm wavelength light. These wavelengths correspond to blue light in the visible spectrum. Light wavelengths corresponding to red light penetrate deeper into the

cell than blue, though they are outside the optimum photoexcitation coefficient. However, red light displays anti-inflammatory properties by influencing cytokine release from macrophages (5).

Photodynamic therapy using blue light has been shown to significantly reduce acne lesions in studies on mild to moderate, inflammatory and pustular acne when irradiating over eight to 10 treatments (8–12). This improvement has been in conjunction with greater patient satisfaction and has been side effect-free.

Papageorgiou et al. (12) investigated the effects of a combination blue and red light treatment in a randomized study of 107 patients with mild to moderate acne. Results displayed a 76% reduction in inflammatory lesions in the combination group. This result was significantly superior to that achieved by blue light alone.

The objective of this study was to evaluate the efficacy of a combination of 415 nm blue and 633 nm red light in the reduction of inflammatory lesions in both mild/moderate and severe acne patients using a total of eight light treatments over a 4-week period.

## Materials and methods

### Subjects

A total of 24 subjects with mild to severe symmetric facial acne vulgaris as defined by Burton classification gradings III–VI were recruited for the study. All subjects were recruited from the outpatient clinic of Advanced Laser & Dermatological Surgery Clinics PC, Beaverton, OR, USA during March 2004. Subjects were matched at baseline in terms of both age and duration of acne. All subjects were Fitzpatrick skin types II–V.

Exclusion criteria were use of oral or topical agents during the 6 weeks preceding the trial, oral retinoid use in the previous 9 months, history of photosensitivity disorder and pregnancy or lactation.

All subjects were screened prior to treatment and a full medical history recorded. All subjects gave informed written consent to inclusion in the trial.

All subjects were allocated to a single whole-face treatment group. No control group was used in this study.

### Light source

Two separate hinged planar arrays of light-emitting diodes (LEDs) were used for treatment: Omnilux blue<sup>TM</sup> delivering non-coherent blue light at 415 nm wavelength, 40 mW/cm<sup>2</sup> intensity, total dose 48 J/cm<sup>2</sup> after 20 minute exposure; and Omnilux revive<sup>TM</sup> delivering non-coherent red light at 633 nm wavelength, 80 mW/cm<sup>2</sup>, total dose 96 J/cm<sup>2</sup> after 20 minute exposure (Omnilux blue and

Omnilux revive, Phototherapeutics Ltd, Altringham, Manchester, UK).

### Study design

All subjects received a total of eight light therapy treatments to the entire face over a 4-week treatment period. Light treatments were two per week for the four treatment weeks: one blue (415 nm) and one red (633 nm) light treatment in each week. All light therapy sessions were of 20-minute duration. A minimum of three intervention-free days was enforced between each light treatment.

Each subject received a gentle facial wash followed by treatment with aluminium oxide crystal microdermabrasion (5-minute treatment time per full face) prior to each light treatment. At each treatment, the light source was positioned approximately 1 cm from the patient's nose tip for the entire treatment duration. Recommended eye protection was implemented at all light treatments.

All subjects were advised to avoid tactile contact with lesions between treatments.

### Clinical assessments

Included subjects were issued with non-medicated soap for a 2-week washout period.

Burton acne grading and Fitzpatrick skin type were recorded for all subjects at baseline.

Acne assessments were conducted using lesion counts that included the entire face from hairline to jawline. Lesions included in the count were all comedones, papules, pustules and nodules. Each lesion present was assigned a value of '1' in the lesion count. Acne was assessed at baseline and at weeks 2, 4, 8 and 12. Assessments were conducted by the non-blinded principal investigating dermatologist.

Digital photographs (Canon<sup>®</sup> 300D digicam) for lesion assessment were taken of all subjects at baseline, and at 2, 4, 8 and 12 weeks. Head position, angle, framing, exposure and lighting conditions were standardized for all photographs.

The investigator's and subject's overall assessment of the treatment was recorded after the final treatment and at the 12-week point.

### Statistical methods

Statistical significance of lesion count reductions from baseline and at the 4- and 12-week follow-up were analysed by standard Student's *t*-test using a confidence level of  $p=0.001$ .

## Results

A total of 24 subjects were included in the study. Subjects were well matched at baseline in terms of

Table I. Mean reduction in lesion count at baseline, and at 2, 4, 8 and 12 weeks of follow-up.

	Baseline	Week 2	Week 4	Week 8	Week 12
Mean lesion count	26	18	14	8	5
Mean % reduction	–	31	46	69	81

both age and duration of acne. Included subjects were Fitzpatrick skin types II–V.

In all, 22 subjects (13 male, nine female, mean age 20 years, range 16–29) completed follow-up. Five subjects had Burton grade III acne, four were grade IV, eight were grade V and five were grade VI.

Two subjects withdrew from the study due to personal circumstances unrelated to the trial. These subjects' data were subsequently excluded from analysis.

The mean percentage reduction in lesion count at all follow-up points is detailed in Table I.

A mean reduction in lesion count was observed at all follow-up points. At the 4-week follow-up, the mean lesion count reduction was significant at 46% ( $p=0.001$ ). At the 12-week follow-up, the mean lesion count reduction was also significant at 81% ( $p=0.001$ ) (Figure 1).

Comparing the lesion count reduction at the 12-week follow-up between those subjects with mild to moderate acne (Burton grades III and IV) and those with severe acne (Burton grades V and VI), those with a mild to moderate condition showed a mean reduction of 81.3% ( $p=0.01$ ), whilst those with a severe condition exhibited a mean reduction of 82.5% ( $p=0.001$ ).

Assessment of the overall treatment response was made by both the subject and clinician using a model described in a previous study investigating combination light therapy in acne treatment (12). Response was graded as 'worse' ( $\leq 0\%$  effect), 'unchanged' (1–9%), 'mild improvement' (10–39%), 'moderate improvement' (40–59%), 'marked improvement' (60–89%) or 'clearance' ( $\geq 90\%$ ) (Table II).

There were no reports from subjects or the investigating clinician of the overall response being

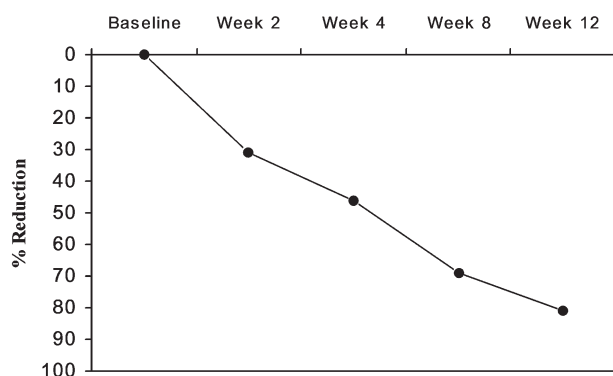


Figure 1. Mean percentage reduction in total lesion count.

graded as 'worse' or 'unchanged'. Investigator and patient assessments were comparable, the majority of subject and clinician assessments, 68% and 59% respectively, graded the light treatment as having 'marked improvement' on acne. At 12 weeks, 9% of subjects reported total clearance; the investigating dermatologist reported this effect in 14% of subjects (Figures 2 and 3).

Two subjects reported side effects of the light treatment in the form of mild facial erythema, occurring after the second and third light treatment respectively. One subject experienced mild bilateral facial erythema; the second subject presented mild erythema confined to the right cheek. These events were self-limiting in both cases and resolved before exclusion was necessary.

## Discussion

The results from this study support earlier findings indicating that combination red and blue light therapy is a safe and efficacious treatment for acne vulgaris.

Lesion counts progressively reduced throughout the 4-week light therapy period and continued to reduce from weeks 4 to 12. This is in keeping with the proposed photobiomodulation cellular effects attributable to light treatment using a non-thermal LED light source for acne treatment. A substantial and significant 81% reduction in mean lesion count was observed at the final 12-week follow-up.

Interestingly, when comparing the responses to light treatment of varying severity acne, subjects with severe acne ( $n=13$ ) had a marginally better response to light therapy than did subjects with a mild/moderate condition ( $n=9$ ). The mean lesion reduction at the 12-week follow-up for the severe acne patients being 82.5% ( $p=0.001$ ).

Although statistical analysis of individual lesions was not performed as part of this trial, it was clinically evident that whilst the light therapy course achieved considerable reduction in papules, pustules and nodules, comedone counts were minimally affected. This may be an indication for the addition of an anticomedonal preparation used adjunctively with light therapy treatments for acne.

The combined LED therapeutic regimen was well received by subjects, with 77% reporting a 'marked effect' of treatment or 'complete clearance' at final follow-up. None of the included subjects reported their acne to be 'worse' or even 'unchanged' after light treatment. The assessment of the treating clinician echoed these feelings: 73% of subjects being considered as achieving a 'marked reduction' or 'complete clearance' of lesions.

The pathogenesis of acne is still not fully understood. However, one of the key factors in the context of acne light therapy is the multiplication of *P. acnes* in the follicular canal. The presence in the sebaceous

Table II. Percentage subject and clinician assessment of overall treatment effect.

	Mild improvement (10–39%)	Moderate improvement (40–59%)	Marked improvement (60–89%)	Clearance ( $\geq 90\%$ )
% Subject assessment	14	9	68	9
% Clinician assessment	5	22	59	14

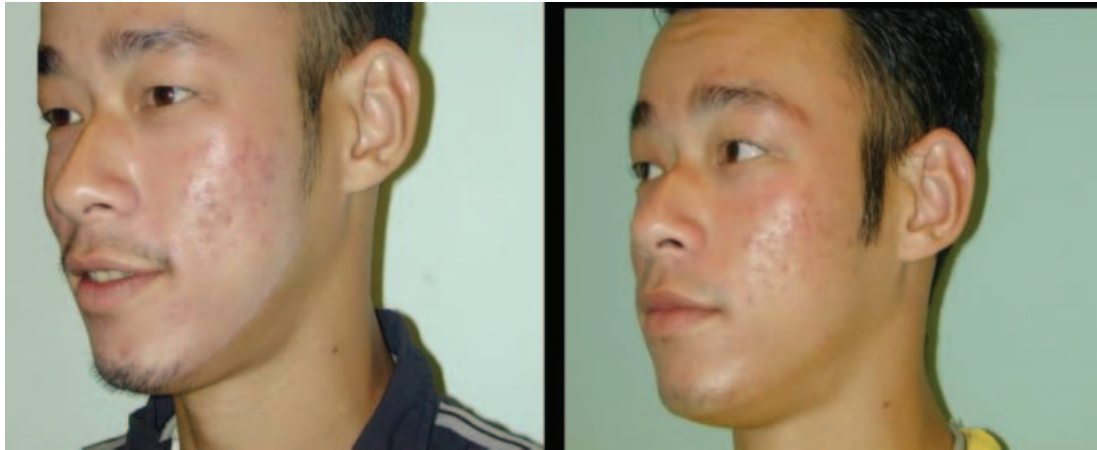

Figure 2. Before and after combined blue and red LED acne treatment.

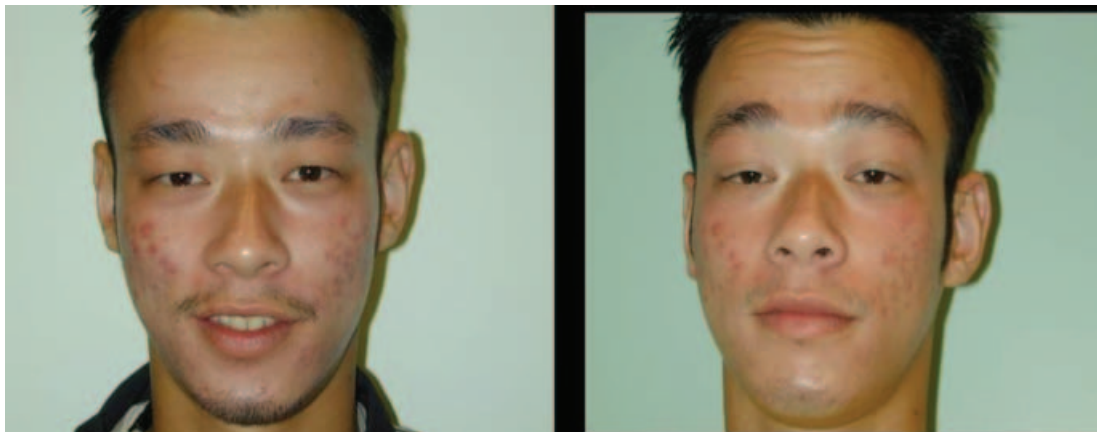


Figure 3. Before and after combined blue and red LED acne treatment.

glands of actively replicating *P. acnes* bacteria has been associated with the production of pro-inflammatory cytokines from keratinocytes in the basal layer of the epidermis. These cytokines include interleukin 1 (IL-1), tumor necrosis factor (TNF) and granulocyte/macrophage colony stimulating factor (GM-CSF) (13).

Previous work has demonstrated efficacy in the use of combination red and blue light delivered simultaneously. Daily, 15-minute treatments over 12 weeks achieved a mean reduction in inflammatory lesions of 76% compared with 63% for blue alone (12).

Of note, Karu has demonstrated that when cell lines were exposed to blue and red light simultaneously there was a marked inhibition of cell activity compared to red and blue light delivered independently (13).

Blue light therapy (415 nm) is effective at activating coproporphyrin III and protoporphyrin IX, subsequently destroying the *P. acnes* bacteria. There is a marked correlation between the reduction in numbers of *P. acnes* bacteria and clinical improvement in patients with acne (14). Red light (633 nm) is less effective at activating coproporphyrin III than blue light, but is a potent activator of protoporphyrin IX, also found in *P. acnes* bacteria (7). Since red light penetrates deeper into tissue than blue, it is possible that red light actively destroys *P. acnes* bacteria residing in the lower regions of the sebaceous gland. Furthermore, red light has noted anti-inflammatory properties. Young et al. demonstrated that red light influences the production of anti-inflammatory cytokines from macrophages while at the same time increases synthesis of

fibroblast growth factor (FGF) from photoactivated macrophage-like cells (15).

It may well be that the primary phototoxic action of 415 nm blue light kills some of the *P. acnes* and severely weakens the remaining *P. acnes* in the acne lesion through an oxidative-mediated apoptotic process. Further illumination with 633 nm not only enhances the bacterial kill rate through protoporphyrin-mediated photodynamic therapy but activates macrophage cells, in conjunction with 633 nm-activated neutrophils, initiating the proliferation stage of wound healing. Photobiomodulated fibroblasts work to repair the damaged dermal matrix, further aided by the FGF produced by macrophages.

The effect of visible red light on the local vasculature is also well recognized. The red light will bring more oxygen and nutrients into the area, further helping to reduce inflammation and enhance the wound repair process (16,17). Study at a cellular and subcellular level is still required to examine this hypothesis.

Further study is indicated to determine both the optimal regimen of light therapy and the most effective patient selection criteria for LED light treatment of acne. Analysis of the reduction in individual lesion types might also assist our understanding of the reaction of different lesions to light therapy. Finally, it must be recognized that this is a pilot study. The addition of a control group or unirradiated half-face to the study design is essential to our understanding of the effects of photodynamic therapy in acne vulgaris.

## References

- Burton JL, Cunliffe WJ, Stafford I, Shuster S. The prevalence of acne vulgaris in adolescence. *Br J Dermatol*. 1971;85:119–26.
- Cooper AJ. Systematic review of *Propionibacterium acnes* resistance to systemic antibiotics. *Med J Aust*. 1998;169:259–61.
- Feldman S, Careccia RE, Barham KL, Hancox J. Diagnosis and treatment of acne. *Am Fam Physician*. 2004;69:2135–6.
- Webster GF. Inflammation in acne vulgaris. *J Am Acad Dermatol*. 1995;33:247–53.
- Lee WL, Shalita AR, Poh-Fitzpatrick MB. Comparative studies of porphyrin production in *P. acnes* and *P. granulosum*. *J Bacteriol*. 1978;133:811–15.
- Kjelstad O, Johnsson A, Sandberg S. Influence of pH on porphyrin production in *P. acnes*. *Arch Dermatol Res*. 1984;276:396–400.
- König K, Ruck A, Schneckenburger H. Fluorescence detection and photodynamic activity of endogenous protoporphyrin in human skin. *Optical Engineering*. 1992;31:1470–4.
- Morton CA, Scholefield RD, Whitehurst C, Birch J. An open study to determine the efficacy of blue light in the treatment of mild to moderate acne. *J Dermatol Treat*. 2005;16:219–23.
- Kjeldstad B, Johnsson A. An action spectrum for blue and near ultraviolet inactivation of *P. acnes*. *Photochem Photobiol*. 1986;43:67–70.
- Sigurdson V, Knulst AC, van Weelden H. Phototherapy of acne vulgaris with visible light. *Dermatology*. 1997;194:256–60.
- Meffert H, Gaunitz K, Gutewort T, Amlong UJ. Acnetherapie mit sichtbarem licht. *Dermatol Monatsschr*. 1990;176:597–603.
- Papageorgiou P, Katsambas A, Chu A. Phototherapy with blue (415nm) and red (660nm) light in the treatment of acne vulgaris. *Br J Dermatol*. 2000;142:973–8.
- Karu T. Primary and secondary mechanisms of action of visible to near IR radiation on cells. *J Photochem Photobiol B*. 1999;49:1–17.
- Cunliffe WJ, Goulden V. Phototherapy and acne vulgaris. *Br J Dermatol*. 2000;142:853–6.
- Young S, Bolton P, Dyson M, Harvey W, Diamantopoulos C. Macrophage responsiveness to light therapy. *Lasers Surg Med*. 1989;9:497–505.
- Niinikoski J. Current concepts of the role of oxygen in wound healing. *Ann Chir Gynaecol*. 2001;90(Suppl 215):9–11.
- Davidson JD, Mustoe TA. Oxygen in wound healing: more than a nutrient. *Wound Repair Regen*. 2001;9:175–7.